

Calcium Oxide as a Root Filling Material: a Three-Year Prospective Clinical Outcome Study

Stephen M. Koral*

Private practice, 2006 Broadway, Boulder, CO 80302, USA

Abstract: Calcium oxide, available for decades as a root canal filling material, has been little used in recent years due to its lack of radio-opacity, and an expectation that it would lead to an excess of root fractures. In this study, four general dentists submitted 79 cases of endodontically treated teeth whose roots were filled with either Biocalex 6/9, or Endocal-10, and rendered adequately radio-opaque with yttrium oxide. Fifty-seven teeth were available for follow up at three years. Criteria for success were comfort, function, radiographic signs of healing. The overall success rate was 89%. The percentage of teeth retained in function was 98%; aside from one equivocal case, no teeth were lost due to root fractures. These numbers are indistinguishable from success rates reported for conventional root filling materials. Conclusion: Calcium oxide may be considered as a safe and viable alternative to other current methods of root obturation.

Key Words: Root canal filling, calcium oxide, calcium hydroxide, endodontic outcomes.

CALCIUM OXIDE AS A ROOT FILLING MATERIAL: A THREE-YEAR PROSPECTIVE CLINICAL OUTCOME STUDY

Root canal therapy has always depended on the bedrock principles of instrumentation, canal disinfection, and obturation, but there has been relatively little attention given to disinfection of the deeper, microscopic spaces in the root, the dentinal tubules. There hasn't been a consistently successful technique for disinfecting the tubules. Canal irrigants don't penetrate very deeply into the tubules [1], and three dimensional obturation techniques, while they can often reach lateral canals and isthmuses, don't enter the tubules either. Interest in more penetrating disinfection may be revived by new high tech methods, such as the radially-firing endo tips for the Waterlase® [Biolase, Irvine, CA], or the cannula for fumigating canals with ozone using the forthcoming Healozone® unit [Kavo, Lake Zurich, IL].

Meanwhile, the classic method of deepening the disinfection of root canals and the associated dentinal tubules has been to use a treatment dressing of calcium hydroxide, often mixed with chlorhexidine or iodine, that is left in the canal between appointments. However, calcium hydroxide preparations were never suitable for long term root fillings because they remain soluble and subject to leaking and washing out. For many years, at the fringes of dentistry, there has been another material for permanent filling of root canals that merges the advantages of calcium hydroxide with a hard setting, canal sealing, three dimensional obturation: calcium oxide [CaO].

Although CaO was introduced as an endodontic filling material by Bernard in 1952 [2], the decades since have seen

remarkably little clinical research on it. In fact, a search of the literature yields not even one longitudinal clinical follow-up study. There have been limited case reports and opinion pieces, and a few papers describing its properties in extracted teeth. In vitro studies have established that CaO root fillings are biocompatible [3]; produce high alkalinity throughout the thickness of the dentin [4]; dissolve organic predentin, resulting in an intimate apposition of the material to the dentin wall [5]; produce a translocation of calcium into dentinal tubules [6]; and produce an apical seal that is resistant to dye penetration [7]. The fact remains, though, that CaO has not been studied clinically in an organized way.

On the face of it, CaO should be an advantageous root filling material, giving the treated root the benefit of what might essentially be a perpetual calcium hydroxide treatment, while setting hard and providing an apical seal. However, there have been three persistent objections to its use. First, the commercial products that have been available for the CaO technique, Biocalex 6/9 [Spad Laboratories, Saint Quentin en Yvelines, France], which is no longer on the market, and Endocal-10 [Albuca, Montreal, Canada], have not been radio-opaque enough to be distinguished from tooth structure. This problem has been solved with the addition of non-toxic, moderately radio-opaque yttrium oxide, as will be described in this paper. Second, the expansive nature of CaO in an aqueous environment has led to the fear that the material will expand with force and fracture of the roots of teeth treated with it. While the proponents of CaO have maintained that it acts more by penetration of the tooth structure, does not expand with force, and does not cause excess root fractures, the perception of it as a hazard still prevails [8]. This anticipation of negative outcomes has prevented the endodontic community from embracing the CaO technique, leading to the third objection: the lack of validation from university based research.

The fact that no academic endodontic program teaches the use of CaO as a root filling material means, conse-

*Address correspondence to this author at the Private practice, 2006 Broadway, Boulder, CO 80302, USA; Tel: 303-443-4984; Fax: 303-443-0842; E-mails: skoraldmd@sugarloaf.net; koraldmd@indra.com

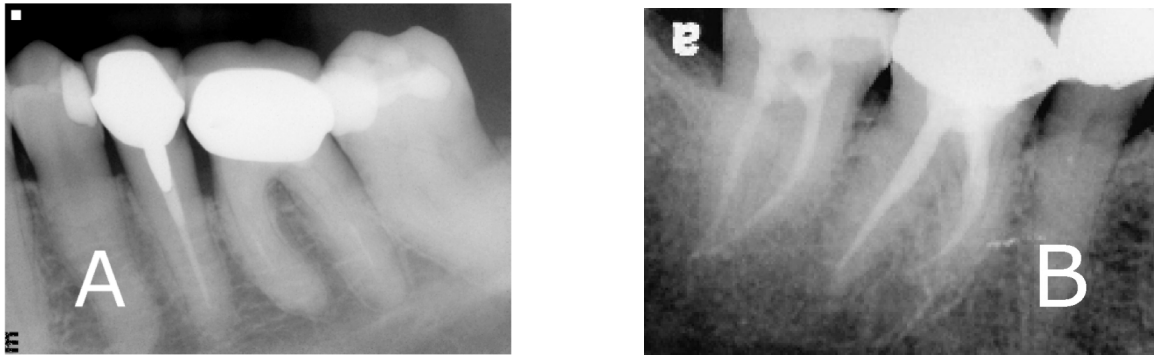


Fig. (1). Shows tooth #19 (36) eight years after it was treated with Biocalex 6/9. The clinical outcome is good but the lack of radio-opacity of the filled root is unacceptable. In figure B, tooth #30 (46) is filled with conventional gutta percha, while #31 (47) is filled with the CaO/Y₂O₃ material, and has acceptable radio-opacity.

quently, that they lack the cases with which to do clinical research. If the outcomes of this technique are to be examined, it must necessarily fall to the private clinicians who use it to provide the material for such studies. This paper reports on prospectively collected clinical observation data derived from root canal treatments done in private general practice. It is not a report of a randomized clinical trial, and it is the author's hope that the information presented here may provide a justification for such a clinical trial at an appropriate academic institution.

MATERIALS AND METHODS

Four general dentists in private practice, who routinely provide endodontic services, and use CaO as their root filling material of choice, submitted cases to this study. Issues of diagnosis, indications for treatment, and informed consent for root canal treatment with CaO, were handled privately between doctor and patient, but each patient whose case was submitted signed written permission to communicate his or her private data to the study. None of the participating dentists had any connection, financial or otherwise, with the manufacturers of the products used in this study.

Cases eligible to be included in the study were any teeth whose endodontic treatment was performed successfully, without compromises in the initial treatment result, that had a reasonable chance of surviving into the future. Criteria for exclusion were:

- Primary teeth
- Previous endodontic treatment
- Excess periodontal risk
- Evident root fracture
- History of full or partial avulsion
- Non-restorable
- Procedural errors in initial treatment, e.g. inability to fully instrument and fill roots; perforation; broken instruments; etc.

Biocalex 6/9 and Endocal-10 were used in this study without distinction, because they were manufactured using identical formulas. The participating dentists were provided by the author with 99.99% pure yttrium oxide powder [Alfa

Aesar, Ward Hill, MA], to improve the radio-opacity of the CaO paste. Yttrium oxide [Y₂O₃] is nearly identical to zinc oxide in its physical and chemical properties [9], is non-toxic [10], and is moderately radio-opaque. It has been approved by the US Food and Drug Administration as a substitute for zinc oxide in this application [11].

The original manufacturer's instructions for Biocalex 6/9 recommended that in cases where the canal was instrumented to its full length, that one-third more zinc oxide be added to the mix. In this study, we substituted yttrium oxide for this extra zinc oxide, which solved the problem of lack of radio-opacity without changing the working properties of the root filling material. Fig. (1A) shows tooth #19 (36) eight years after it was treated with Biocalex 6/9. The clinical outcome is good but the lack of radio-opacity of the filled root is unacceptable. In Fig. (1B), tooth #30 (46) is filled with conventional gutta percha, while #31 (47) is filled with the CaO/Y₂O₃ material, and has acceptable radio-opacity.

The intent of this study was to follow up on the use of the CaO technique in the context of root canal treatment as it is practiced in every day general dentistry, with all the inherent variations that exist between operators. Therefore, no attempt was made to standardize instrumentation, irrigation, use of inter-appointment treatment dressings, or other treatment strategies available to the clinicians. Since the CaO is a paste filling material, it was recommended that they use a wide root preparation design, to allow free passage of a Lentulo spiral to the full working length.

Before declaring the case successfully treated and reporting it to the study, the treating dentist was asked to confirm, on a follow-up appointment, that the paste filling had fully hardened. It is a peculiarity of the CaO root filling that, while it usually hardens on the first application, it doesn't always. It is necessary to examine the hardness of the root filling before proceeding with restorative procedures. Only when the hardness of the root filling had been confirmed by the treating dentist would the case be eligible for registration in the study for prospective follow-up.

Initial clinical data included information on the patient's demographic data, signs and symptoms, and on the vitality or non-vitality of the pulp. Radiographs of diagnostic quality were also submitted.

Follow-up data were collected at one year and three years following initial treatment and submission to this study. Questions asked on the data reporting form related to the classical criteria of endodontic success, after Bender [1966] [12]:

- 1- Absence of pain or swelling
- 2- Disappearance of any sinus tracts
- 3- No loss of function
- 4- Radiographic evidence of resolved or arrested areas of rarefaction after a post-treatment interval of one year

To be considered successful, a case would, in addition, have to have undergone no form of retreatment, and have been restored in a way to provide an adequate coronal seal.

RESULTS

Seventy-nine cases of teeth whose roots were filled with CaO were submitted to this study. The author provided 57 of these cases; Dr. C. L., of Ocala, Florida submitted thirteen cases; Dr. J. S., of Chicago, Illinois submitted six cases; and Dr. S. F., of Calgary, Alberta submitted three cases. Age and gender distribution was as follows: 41 female, 38 male; ages ranged from 15 to 74, with mean age being 48. The sample size decreased to 67 at one year, and 57 at three years, due to the normal attrition of a patient cohort in private practice.

At the one year follow up, three teeth were judged to be endodontic failures, out of 67 cases, yielding a success rate of 95.6%. One tooth had required retreatment, one was judged to have had an increase in the size of the apical radiolucency, and one tooth suffered a root fracture, and was extracted.

At the three year follow up, there were three additional endodontic failures. One tooth was retreated prograde, one underwent apical surgery, and one more had an increase in the size of the apical radiolucency. Three teeth had suffered non-endodontic failures: two were extracted for recurrent caries, and one for a fracture through the furcation. If these three are excluded from the sample, the overall endodontic success rate at three years is 48 out of 54, or 89%. However, of the six teeth that were considered endodontic failures, only one was extracted, yielding a rate of 98% of the treated teeth that were still present in function at the three year follow-up.

Of the original 79 cases, 51 were non-vital, while 28 had vital pulp tissue. At the one-year follow up, 43 of 45, or 95.5% of the non-vital cases were successful, and 20 of 21, or 95.5% of the vital cases were successful. At the three year

follow up, 32 of 35, or 91.4% of the non-vital cases were successful, while 16 of 19, or 84.2% of the vital cases were successful. Two of the vital cases underwent retreatment during that time, and were thus classified as failures by the criteria established at the beginning of the study.

DISCUSSION

Under the prevailing standard of obturating root canals with gutta percha and sealers, the CaO technique has seen relatively little use in recent years. It was most popular in Europe during the 1980's, and although Biocalex 6/9 became available in the United States by the early 1990's, it attracted little attention. However, a number of the dentists who tried it have stayed with it ever since. Anecdotally reported results have been very good, with none of the excess root fractures predicted by critics of the technique.

In this study of 79 cases, there was only one tooth that suffered a vertical root fracture. Interestingly, the fracture was diagnosed two weeks after the initial treatment was completed. The patient's symptoms of pain and tenderness did not relent during the brief post-treatment period, leading to the likely conclusion that the tooth had had an undetected root fracture prior to treatment that was not caused by the CaO root filling.

A 2004 paper by Goldberg [7], reinforced the idea that filling root canals with CaO would result in a high percentage of fractured teeth. His experiment involved 15 extracted human lower incisors that had been instrumented and filled with Endocal-10, and held in a humidor at 37°C, for 1, 7, and 30 days. Two of the teeth were found to have a vertical fracture after one day, and one more at seven days, resulting in a 20% rate of root fracture. The outcomes reported in the current study – no root fractures after three years, except for the one equivocal case mentioned above – do not bear out Goldberg's findings in clinical terms. There is no obvious explanation for a discrepancy of this magnitude. It is possible that storing treated teeth in 100% humidity, as Goldberg did, does not adequately reproduce the wet conditions that occur *in vivo*. CaO is extremely hygroscopic. It is this author's experience that extracted teeth, when instrumented and filled with CaO and left dry on the bench, will become completely desiccated within a few days, and 100% of them will fracture. This moisture gradient in the ambient environment, from the dry bench top, to the humidor, to the living mouth, may account for the difference in results.

Papers on clinical outcomes of root canal treatment vary in significant ways, including the clinical setting involved, retrospective versus prospective follow-up, and criteria of clinical success [13-20]. Some use only retention of teeth as

Results	One Year Follow-up	Three Year Follow-up
Endodontic success according to strict criteria	64/67 95.6%	48/54 88.9%
Teeth retained in function	66/67 98.5%	53/54 98%

the criterion of success, some present data on comfort and functionality, and some include radiographic findings as well. This study has used the classical criteria of Bender et al. that require comfort, function and radiographic evidence of periapical healing to define success. Additionally, we have required coronal seal, and we have excluded retreatment in any form from the definition of success, resulting in a stringent standard relative to much of the literature.

There is general agreement that problems with root canal treatments tend to show up within the first three years, and therefore, three years should be a long enough time to demonstrate the acceptability of a root treatment technique [21]. Given those considerations, the results of the three year follow up reported here place the outcomes of the CaO treatments squarely in the range of success rates widely reported in the literature. The general consensus, synthesizing roughly from the many and disparate reports, is that root treatment of teeth without apical periodontitis has long term clinical success about 90% of the time, while treatment of teeth with apical periodontitis has long term clinical success about 80% of the time. The overall three year success rate of root treatments reported in this study, including vital and non-vital cases, was 88.9%.

Alley, [22] found that general dentists, like those participating in this study, had a success rate of 89.7%, based solely on the criterion of retention of teeth at 5 years. The endodontists they studied had a better retention rate, 98.1%. Ng *et al.*, [23] conducted a meta-analysis of endodontic outcome papers spanning eighty years of literature. Their “estimated weighted pooled success rates” were between 68% and 85% when strict criteria were used. Salehrabi and Rotstein [16] examining a nationwide database of nearly 1.5 million root canal treatments, reported an overall 97% rate of retention after eight years, without regard to more discriminating criteria such as retreatment or radiographic signs.

Several teeth in this study, judged to be failures on the basis of strict criteria, have been retained by means of retreatment, or despite expansion of a periapical radiolucency. If the criterion of success had been merely retention of teeth, the overall success rate would have been 98%. This demonstrates that despite inter-operator variables, and the many hazards and uncertainties of endodontic treatment, teeth whose canals were filled with CaO were surviving at the same rate as those reported upon in the extant literature on conventional root filling methods. One potential source of bias in the study was the loss of 22 cases in the follow up period of 3 years. Additional failures could have come to light in a group representing 28% of the original sample.

As mentioned, dentists who have continued to perform CaO root fillings through the decades since its introduction have reported, anecdotally, very good experiences. No data exist to support or deny a claim that the highly alkaline nature of the material results in a greater degree of disinfection of the root than conventional methods, although its relation in chemistry to calcium hydroxide may lead to that speculation. While current techniques of root obturation are highly developed, and show constantly improving ability to seal the canals, none of them contain active ingredients that can provide ongoing disinfection. CaO has, at least, that potential.

Further study to explore this potential advantage of CaO would contribute in a substantive way to endodontic science.

The current study does show, however, that filling endodontically treated roots with CaO produces clinical results that are indistinguishable from conventional methods, without incurring an excessive rate of root fractures. With the addition of yttrium oxide, CaO can be made radio-opaque to an acceptable degree. CaO should be considered a safe and viable alternative to other current methods of root obturation.

ACKNOWLEDGEMENT

The author acknowledges the financial and logistical support of the International Academy of Oral Medicine and Toxicology (IAOMT).

REFERENCES

- [1] Berutti E, Marini R, Angeretti A. Penetration ability of different irrigants into dentinal tubules. *J Endod* 1997; 23(12): 725-7.
- [2] Bernard PD *Therapie Ocalexique*, Paris: Editions Maloine 1967.
- [3] Guigand M, Pellen-Mussi P, Le Goff A, Vulcain JM, Bonnaure-Mallet M. Evaluation of the cytocompatibility of three Endodontic materials. *J Endod* 1999; 25: 419-423.
- [4] Minana M, Carnes DL, Walker WL. pH changes at the surface of root dentin after intracanal dressing with CaO and calcium hydroxide. *J Endod* 2001; 27: 43-45.
- [5] Guigand M, Vulcain JM, Dautel-Morazin A, Bonnaure-Mallet M. An ultrastructural study of root canal walls in contact with endodontic biomaterials. *J Endod* 1997; 23: 327-330.
- [6] Guigand M, Vulcain JM, Dautel-Morazin A, Bonnaure-Mallet M. *In vitro* study of intradental calcium diffusion induced by two Endodontic biomaterials. *J Endod* 1997; 23: 387-390.
- [7] Goldberg RA, Kuttler S, Dorn SO. The properties of Endocal-10 and its potential impact on the structural integrity of the root. *J Endod* 2004; 30: 159-162.
- [8] American Association of Endodontists. Position Statement on Biocalx. American Association of Endodontists 2000.
- [9] Handbook of Chemistry and Physics, 73rd Ed. David R. Lide, editor. Boca Raton, Florida: CRC Press 2002.
- [10] Meditext Medical Management, in TOMES System, KM Hurlburt, editor. Englewood Colorado: Micromedex, Inc, 2001.
- [11] http://www.accessdata.fda.gov/cdrh_docs/pdf/k010176.pdf accessed July 28, 2010.
- [12] Bender IB, Seltzer S, Soltanoff W. Endodontic success – a reappraisal of criteria. *Oral Surg* 1966; 22: 790-802.
- [13] Ingle JI, Beveridge EE, Glick DH, Weichman JA. Endodontic success, failure – the Washington Study. In: *Endodontics*, 4th edition, Malvern PA: Williams & Wilkins 1994; 21-52.
- [14] Friedman S, Abitbol S, Lawrence HP. Treatment outcomes in endodontics: the Toronto study. Phase I: initial treatment. *J Endod* 2003; 29: 787-93.
- [15] Farzaneh M, Abitbol S, Lawrence HP, Friedman S. Treatment outcomes in endodontics – the Toronto study. Phase II: initial treatment. *J Endod* 2004; 30: 302-9.
- [16] Salehrabi R, Rotstein I. Endodontic treatment in a large patient population in the USA: an epidemiological study. *J Endod* 2004; 30: 846-50.
- [17] Tilashalski KR, Gilbert GH, Boykin MJ, Shelton BJ. Root canal treatment in a population-based adult sample: status of teeth after endodontic treatment. *J Endod* 2004; 30: 577-81.
- [18] Dammaschke T, Steven D, Kaup M, Ott KH. Long term survival of root-canal-treated teeth: a retrospective study over 10 years. *J Endod* 2003; 29: 638-43.
- [19] Benennati FW, Khajotia SS. A radiographic recall evaluation of 894 endodontic cases treated in a dental school setting. *J Endod* 2002; 28: 391-5.
- [20] Barbakow FH, Cleaton-Jones P, Friedman D. An evaluation of 566 cases of root canal therapy in general dental practice. 2. Postoperative observations. *J Endod*. 1980; 6: 485-9.
- [21] Rotstein I, Salehrabi R, Forrest JL. Endodontic treatment outcome: survey of oral health care professionals. *J Endod* 2006; 32: 399-403.

- [22] Alley BS, Kitchens GG, Alley LW, Eleazer PD. A comparison of survival of teeth following endodontic treatment performed by general dentists or by specialists. *Oral Surg Oral Med Oral Pathol Oral Radiol Endod.* 2004; 98: 115-8.
- [23] Ng YL, Mann V, Rahbaran S, Lewsey J, Gulabivala K. Outcome of primary root canal treatment: systematic review of the literature - part 1. Effects of study characteristics on probability of success. *Int Endod J* 2007; 40[12]: 921-39.

Received: April 19, 2010

Revised: September 30, 2010

Accepted: October 15, 2010

© Stephen M. Koral; Licensee *Bentham Open*.

This is an open access article licensed under the terms of the Creative Commons Attribution Non-Commercial License (<http://creativecommons.org/licenses/by-nc/3.0/>) which permits unrestricted, non-commercial use, distribution and reproduction in any medium, provided the work is properly cited.